


PATIENT

Sheba Spiteri

SPECIES

Canine

BREED

Shih Tzu

SEX

Female Spayed

AGE

14 years

WEIGHT

7.9lbs

INTERPRETED BY

 Maggie Machen Lamy,
 DVM DACVIM
 (Cardiology)

IMAGING PERFORMED BY

Kelly Reschny, RVT

HOSPITAL NAME

 Hamilton Region
 Veterinary
 Emergency Clinic

REFERRING VET

Dr. Rubino

PRESENTING CLINICAL SIGNS

History: Presented with bronchopneumonia and possible aspiration pneumonia. Tachypnea and O2 dependent. Chronic IVDD; was running until yesterday. Delayed hind limb proprioception. Recent onset murmur, grade V/VI. Dorsal and hind limb muscle atrophy.

-Current medications: Butorphanol, ampicillin, enrofloxacin, Cerenia, maintenance IV fluids.

-Abnormal PE/Chem/CBC/UA Results (7/5/23): WBC 15.35 (5-16.76) neutrophils 12.57 (11.64) normal urea and creatinine.

-Radiographs: Show bronchopneumonia, cardiomegaly, pleural fibrosis, tracheal membrane, hepatomegaly and renal mineralization.

ECHOCARDIOGRAM FINDINGS

2D, m-mode, color flow and doppler imaging is available. Diffuse thickening of mitral valve leaflets (anterior>posterior) with mild prolapse into the left atrial lumen. Moderate eccentric mitral regurgitation with moderate left atrial dilation. Mildly increased LV diameter with hyperdynamic myocardial function. The tricuspid valve appears subjectively normal, with moderate tricuspid regurgitation. Normal velocity. Normal right atrial and ventricular diameter. The pulmonic and aortic valves are normal in morphology and mobility. Normal pulmonic and aortic outflow velocities. No aortic or pulmonic insufficiency. No pericardial or pleural effusion noted. No cardiac tumors observed.

CARDIAC CHART

CANINE CARDIAC PARAMETERS	MR VMAX (m/s)	TR VMAX (m/s)	LA/AO (Boon method)	LA/AO (Heart Base; Swe)	FS (%)	EF (%)	EPSS (cm)
NORMAL PARAMETER	4.5-5.5	<2.7	1.3	<1.6	28-40	40-100	<0.6
PATIENT	NM	2.6	1.7	1.7	55	92	0.1
CANINE CARDIAC PARAMETERS	HR (BPM)	AV VMAX (m/s)	PV MAX (m/s)	BODY WEIGHT (kg)	LA 2D short axis Base view (cm)	LVIDd Avg; 2D and m-mode short axis (cm)	LVIDs Avg; 2D and m-mode short axis (cm)
NORMAL PARAMETER	50-100	0.7-1.7	0.7-1.6	BELOW	BELOW	BELOW	BELOW
PATIENT	120	0.9	0.7	3.6	2.2	2.9	1.3
*Normal chamber parameters expressed as a mean value (SD)				3	1.27 (5.3)	2.46 (2.46)	1.36 (5.5)
BODY WEIGHT DEPENDENT PARAMETERS				5	1.40 (4.5)	2.74 (5.2)	1.60 (4.7)
*Note: All measurements based upon multi-modal images and methods. An average value is reported.				10	1.50 (3.8)	3.27 (3.5)	2.06 (3.1)
				15	1.83 (2.0)	3.71 (2.4)	2.43 (2.1)
				20	2.02 (1.9)	4.14 (2.2)	2.80 (2.0)
				25	2.18 (2.4)	4.48 (2.9)	3.10 (2.5)
				30	2.33 (3.3)	4.83 (3.9)	3.39 (3.4)
				35	2.48 (4.3)	5.17 (5.0)	3.69 (4.5)
				40	2.62 (5.2)	5.48 (6.1)	3.96 (5.4)
				50	2.88 (7.1)	6.07 (8.3)	4.46 (7.4)

Adapted from June Boon, Veterinary Echocardiography, 1998
 Rishniw M and Hollis NE, J Vet Intern Med 2000; 14:429-435
 Hansson et al, Vet Rad and Ultrasound 2002
 Bonagura et al. Echocardiography: principles of interpretation, Vet Clin North Am 15:1177, 1995

INVOICE

31701

DATE

7/6/23



PATIENT

Sheba Spiteri

SPECIES

Canine

BREED

Shih Tzu

SEX

Female Spayed

AGE

14 years

WEIGHT

7.9lbs

INTERPRETED BY

Maggie Machen Lamy,
DVM DACVIM
(Cardiology)

IMAGING PERFORMED BY

Kelly Reschny, RVT

HOSPITAL NAME

Hamilton Region
Veterinary
Emergency Clinic

REFERRING VET

Dr. Rubino

INVOICE

31701

DATE

7/6/23

INTERPRETATION OF THE FINDINGS & FURTHER RECOMMENDATIONS

Chronic degenerative valve disease causing moderate mitral and tricuspid regurgitation. Moderate left atrial enlargement indicates there is relatively low risk for imminent complication, however risk for progression to spontaneous congestive heart failure in the future is elevated. No additional issues are identified.

These findings would suggest the current respiratory issues are noncardiac in origin as dictated by the CXR report.

Given the risk for progression and results of the EPIC trial, Pimobendan is indicated in this patient as below. Assessment of progression in the future will help predict long term outcome, however prognosis is guarded at this stage (B2).

Omega fatty acid supplementation and mild salt restriction may also be of some long-term benefit. Monitor for development of a progressive cough, labored breathing, exercise intolerance or collapse episodes.

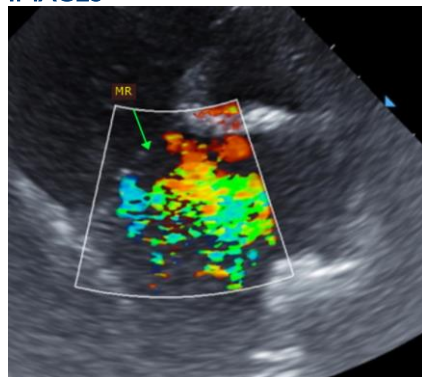
Once on the medication for 3-5 days, anesthetic risk is considered mildly elevated. Cardiac protective drug choices (opioid/benzodiazepine premedication, Propofol or alfaxalone induction, iso or sevo gas) are recommended. Monitor for arrhythmias, hypotension, and hypoxia both intra and post-operatively and intervene as necessary. Judicious IV fluid rates are recommended to avoid fluid overload. Avoid heart rate stimulating drugs such as atropine unless clinically indicated.

PLAN

Institute heart muscle support Pimobendan 0.3mg/kg PO q12h. Consider hydrocodone as discussed.

Recommend monitor for progression with a recheck echocardiogram in 6 months, sooner if any development of clinical signs.

IMAGES





PATIENT

Sheba Spiteri

The information and recommendations provided are based on the images presented by the referring veterinarian. No evaluation can be communicated regarding pathology that was not visible in the image/video clips provided.

SPECIES

Canine

Thank you for this referral. This report was generated using transcription software, and minor dictation errors may be present. If the clinical or image interpretation does not parallel your findings or if I can be of any further assistance, please contact me.

BREED

Shih Tzu

Maggie Machen Lamy, DVM
Diplomate of the American College of Veterinary Internal Medicine (Cardiology)
info@sonopath.com

SEX

Female Spayed

AGE

14 years

WEIGHT

7.9lbs

INTERPRETED BY

Maggie Machen Lamy,
DVM DACVIM
(Cardiology)

**IMAGING
PERFORMED BY**

Kelly Reschny, RVT

HOSPITAL NAME

Hamilton Region
Veterinary
Emergency Clinic

REFERRING VET

Dr. Rubino

INVOICE

31701

DATE

7/6/23